

Breast Tuberculosis or Granulomatous Mastitis: A Diagnostic Dilemma

Dr. Foram Modh¹, Dr. Jenish Sheth²

¹PG Resident, General Surgery Department, SMIMER Medical College, Surat, India

²Guide, Assistant Professor, General Surgery Department, SMIMER Medical College, Surat, India

Abstract: *Breast tuberculosis or granulomatous mastitis: A diagnostic dilemma. Aims and Objectives:- To rule out mammary tuberculosis in developing countries patients presenting with breast lump, Nipple Discharge which may confuse with carcinoma or breast Abscess. Methods: This study was conducted in SMIMER Hospital, Surat, General Surgery department from 2017 to 2019. It was prospective randomized study. We had examined the 100 patient coming in surgery OPD with Complain of breast lump, pain, nipple discharge. The diagnosis was made by FNAC and detection of AFB on cytology and some had on Nipple discharge. Some patients were diagnosed after excision biopsy of lump. 2 patients were diagnosed after doing surgery excision of lump or abscess. Result: Total 100 patients were taken in our study, All female patients were between 30-50 years of age. 60 (60%) patients were came with complain of painless lump at Retroareolar region from them, 30% patients had nipple discharge, 40% patients came with painful lump. 13% Patients were diagnosed Breast tuberculosis from FNAC AFB stain of painless lump. 2 (5%) patients were diagnosed after doing surgery excision of lump or abscess. Discussion Mammary tuberculosis accounts for 3% of breast pathologies in India and is five times less common than carcinoma of the breast. It has been suggested that mammary gland tissue, like spleen and skeletal muscle, offers resistance to the survival and multiplication of the tubercle bacillus. (3) Tewari and Shukla (4) recently classified mammary TB into three categories (a) nodulocaseous tubercular mastitis, (b) disseminated/confluent tubercular mastitis, and (c) tubercular breast abscess. Treatment of breast TB with standard antituberculosis therapy for 6 months usually results in good clinical response. (5) Conclusion: Breast TB is a diagnosis of exclusion should be suspected in patients from endemic countries with poor response to antibiotic therapy and AKT trial is warranted. (Key words: breast tuberculosis, breast*

Keywords: breast tuberculosis, breast lump, AKT treatment

1. Introduction

- TB mostly affects the lungs as it is an airborne infectious disease, but any organ can be affected as a result of hematogenous spread.
- Some organs and tissues like the mammary gland tissue and spleen offer resistance to the survival and multiplication of tuberculosis bacteria. (1)
- Tuberculosis of the breast is an uncommon disease, with an incidence between 0.1%– 3% of all breast diseases treated surgically. (1)

2. Aims and Objectives

- To rule out mammary tuberculosis in developing countries patients presenting with breast lump, Nipple Discharge which may confuse with carcinoma or breast Abscess.
- To suggest that breast TB should be included in the differential diagnosis of breast lesions, like breast carcinoma, persistent breast abscess and infectious patterns with fistulizations, especially for patients from high risk populations and endemic regions.

3. Methods

- This study was conducted in SMIMER Hospital, Surat, General Surgery department from 2017 to 2019. It was prospective randomized study. We had examined the 102 patient coming in surgery OPD with Complain of breast lump, pain, nipple discharge.

- The diagnosis was made by FNAC and detection of AFB on cytology and some had on Nipple discharge. Some patients were diagnosed after excision biopsy of lump.
- 4 patients were diagnosed after doing surgery excision of lump or abscess.

4. Result

- Total 102 (100%) patients were taken in our study. All patients were between 30-50 year females.
- All patients with a breast lump or nodularity were subjected to fine needle aspiration cytology (FNAC) and tissue acid fast bacilli on staining. they had also investigated by routine blood tests, ESR, Chest X-Ray.
- 62 (60.8%) Patients had painless lump. 8 (12.7%) patients were diagnosed breast tuberculosis positive on FNAC with AFB Stain. 2 (3.2%) patients were operated for lump excision biopsy and diagnosed. (Table-1)
- 40 (39.2%) patients had painful tender lump so they were operated. 2 (5%) patients were operated and cavity tissue excision biopsy were positive for breast TB. (Table-2)
- Total 10 (11%) patients had diagnosed breast tuberculosis. One patient was lactating mother. 3 (30%) patients had palpable ipsilateral axillary lymph nodes.
- Mantoux test was positive in 2 (20%) patients and erythrocyte sedimentation rate raised in all patients. Chest radiography revealed pulmonary tuberculosis in 2 (20%) patients which suggesting old parenchymal calcemic lesion.

- The diagnosis of mammary tuberculosis was confirmed by a combination of clinical suspicion and cytological findings.
- All patients received antituberculous therapy comprising rifampicin 450 mg, isoniazid 300 mg, pyrazinamide 1500 mg, and ethambutol 800 mg per day for two months followed by rifampicin and isoniazid for another four months. 4 (40%) patients required surgical intervention of breast tuberculosis positive lump.
- All patients were followed up for a mean period of 3 months.
- Complete resolution was obtained in 8 (80%) patients and 2 (20%) The residual mass was confirmed by repeated FNAC to be fibrotic.

5. Discussion

- Tuberculosis of the breast is extremely uncommon in the western population but accounts for 3% of surgically treatable breast conditions in India. It also found that mammary tuberculosis comprised 3% of breast diseases and was five times less common than carcinoma of the breast (2).
- Primary infection of the breast may occur through skin abrasions or through the duct openings on the nipple. Direct extension from contiguous structures like the underlying ribs is another possible mode of infection. However, it is generally believed that infection of the breast is usually secondary to a tuberculous focus could be pulmonary or a lymph node in the paratracheal, internal mammary, or axillary group. Involvement of the breast in such cases is by haematogenous spread. In our study 2 patients had evidence of old pulmonary tuberculosis while 3 patients had associated axillary lymphadenopathy. (3)
- Lactation is known to increase the susceptibility of the breast to tuberculosis. Shinde *et al* found 7% of their patients to be lactating at the time of presentation, while Banerjee *et al* reported 33% of their patients to be lactating. In our series also 10% of the women were lactating at presentation.
- In these women, perhaps the stress of childbearing and increased vascularity of the breast facilitates infection and dissemination of the bacilli.
- One interesting hypothesis from a series in India correlates a prevalence of tuberculosis in the faucial tonsils of suckling infants with a higher incidence of tuberculosis of the breast in lactating women.
- There are no reports in the literature on the presence of acid fast bacilli in the milk of such women even though it is possible to isolate acid fast bacilli in 12% of breast biopsies. (3, 4)
- Tuberculosis of the male breast is an extremely rare condition. Lilleng *et al*, in a study of 809 cases of male breast mass, did not find a single case of tuberculosis. we did not find male patients with breast TB.
- There are three clinical varieties of mammary tuberculosis—namely, nodular, disseminated, and sclerosing. The nodular variant is often mistaken for a fibroadenoma or carcinoma. The disseminated variety commonly leads to caseation and sinus formation.

Sclerosing tuberculosis afflicts older women and is slow growing with the absence of suppuration (6).

- Tuberculous mastitis can be diagnosed reliably by cytological evidence of epithelioid granulomas, Langhans' giant cells, and lymphohistocytic aggregates.
- Kakker *et al* could confidently diagnose breast tuberculosis in 73% of patients on the basis of FNAC findings of epithelioid cell granulomas with caseous necrosis. In our Study, FNAC or histology was 100% reliable in diagnosing tuberculosis, including patients who had tender nodularity. (7)

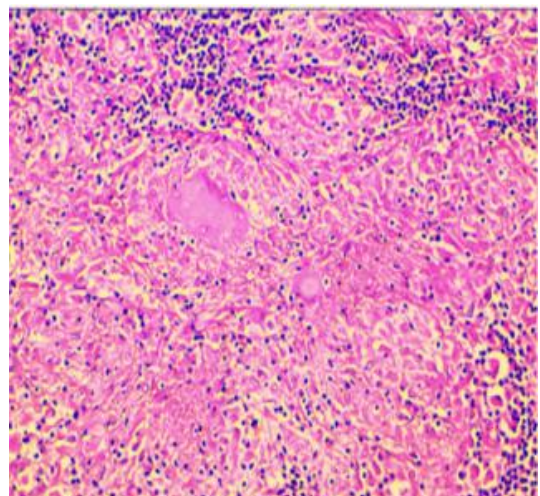
6. Conclusion

Breast TB is a diagnosis of exclusion should be suspected in patients from endemic countries with poor response to antibiotic therapy and AKT Should be started after confirmation of Breast Tuberculosis.

References

- [1] Banerjee SN, Ananthkrishnan N, Mehta RB, Parkash S. Tuberculous mastitis: a continuing problem. *World J Surg*. 1987;11:105–9.
- [2] Hamit HF, Ragsdale TH. Mammary tuberculosis. *J R. Soc Med*1982;75:764
- [3] Shinde SR, Chandawarkar RY, Deshmukh SP. Tuberculosis of the breast masquerading as carcinoma: a study of 100 patients. *Word J Surg*1995;19:379–81
- [4] Arslan A, Ciftci E, Yildiz F, *et al*. Multifocal bone tuberculosis presenting as a breast mass: CT and MRI findings. *Eur Radiol*1999;9:1117–9
- [5] Lilleng R, Paksay N, Vural C, *et al*. Assessment of fine needle aspiration cytology and histo-pathology for diagnosing male breast masses. *Acta Cytol*1995;39:877–81
- [6] Goksoy E, Duren M, Durgun V, *et al*. Tuberculosis of the breast. *Eur J Surg*1995;161:471–3
- [7] Kakker S, Kapila K, Singh MK, *et al*. Tuberculosis of the breast. A cytomorphologic study. *Acta Cytol*2000;44:292–6

1) Positive AFB Stain of breast tissue



2) Breast Lump

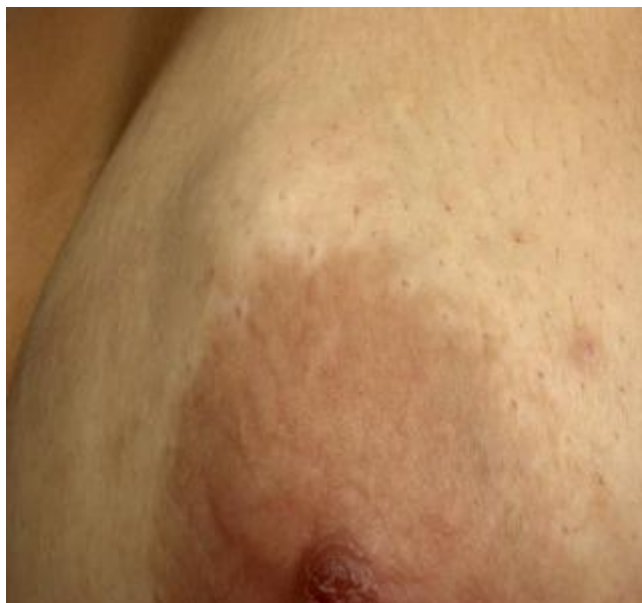

Table 1

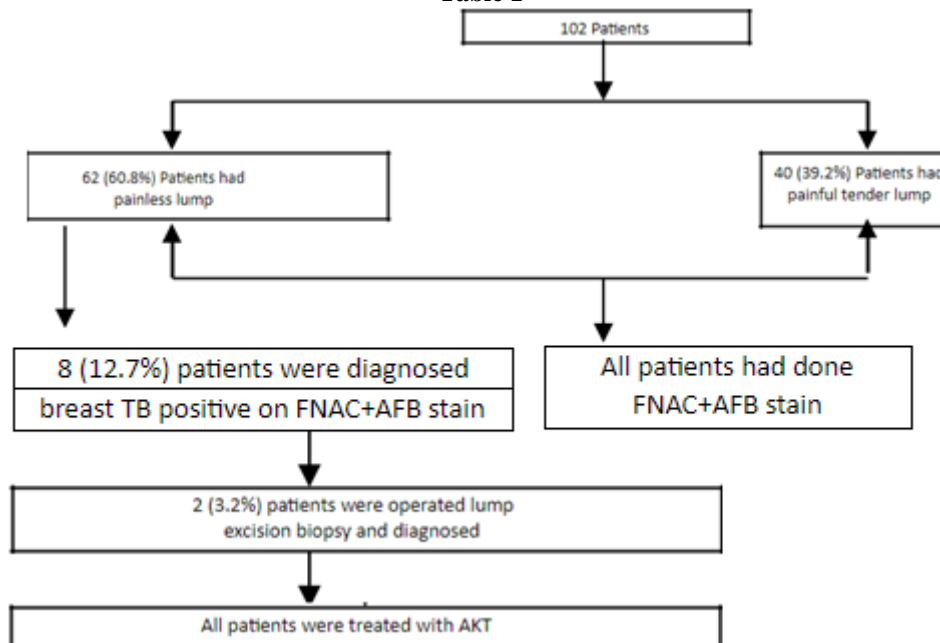


Table 2

